

The efficacy and safety of microneedle monopolar radiofrequency for the treatment of periorbital wrinkles

Soon-Hyo Kwon, Ji-Young Choi, Gun Young Ahn, Woo Sun Jang, Jung-Won Shin, Jung-Im Na, Kyoung-Chan Park & Chang-Hun Huh

To cite this article: Soon-Hyo Kwon, Ji-Young Choi, Gun Young Ahn, Woo Sun Jang, Jung-Won Shin, Jung-Im Na, Kyoung-Chan Park & Chang-Hun Huh (2019): The efficacy and safety of microneedle monopolar radiofrequency for the treatment of periorbital wrinkles, Journal of Dermatological Treatment, DOI: [10.1080/09546634.2019.1662880](https://doi.org/10.1080/09546634.2019.1662880)

To link to this article: <https://doi.org/10.1080/09546634.2019.1662880>



Published online: 10 Sep 2019.



Submit your article to this journal [↗](#)

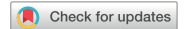

View related articles [↗](#)



View Crossmark data [↗](#)

ARTICLE



The efficacy and safety of microneedle monopolar radiofrequency for the treatment of periorbital wrinkles

Soon-Hyo Kwon^a, Ji-Young Choi^a, Gun Young Ahn^b, Woo Sun Jang^b, Jung-Won Shin^a, Jung-Im Na^a, Kyoung-Chan Park^a and Chang-Hun Huh^a

^aDepartment of Dermatology, College of Medicine, Seoul National University, Seoul National University Bundang Hospital, Gyeonggi, Korea;

^bChungdam Gwoonsesang Dermatologic Clinic, Seoul, South Korea

ABSTRACT

Background: Treatment of periorbital wrinkles is a challenging task because of its anatomical significance and delicate nature.

Objective: The aim of this study was to evaluate the efficacy and safety of a microneedle monopolar radiofrequency (RF) device for treating periorbital wrinkles.

Methods and Materials: This retrospective study involved 21 patients who were treated for periorbital wrinkles using a RF device. The type of microneedle used, clinical photography, VISIA wrinkle score, and adverse events were collected from the medical chart. Two independent dermatologists assessed the photographs.

Results: There were 18 female and 3 male patients with a mean age of 50.24 years. The severity of wrinkle was improved according to photographic assessment and VISIA wrinkle score at 6-month post-treatment. When 21 sites treated with a long microneedle (LMN, 1.5 mm) and the other 21 sites treated with a short microneedle (SMN, 0.8 mm) were compared, significant improvement in the VISIA wrinkle score was observed only in those treated with the LMN. No serious adverse events, including scarring and post-inflammatory hyperpigmentation, occurred.

Conclusions: We demonstrated the efficacy and safety of the microneedle monopolar RF device in treating periorbital wrinkles. The LMN was superior to the SMN in reducing VISIA wrinkle score.

ARTICLE HISTORY

Received 12 August 2019
Accepted 22 August 2019

KEYWORDS

Microneedle; monopolar; periorbital wrinkle; radiofrequency; VISIA

Introduction

Treating periorbital wrinkles is a challenging task because of the anatomical significance and delicacy of the surrounding structures (1). Several efficient and safe therapeutic modalities for the management of periorbital wrinkles, including topical tretinoin, chemical peels, botulinum toxin, dermal filler injections, and energy-based devices, have been introduced to avoid potential eye injury, ectropion, or permanent scarring (2–4). However, no standard treatment for periorbital wrinkles has been established yet (4).

Radiofrequency (RF) is a noninvasive rejuvenating technique that stimulates the production of collagen by heating the dermis (5). Dermal heating initially provokes collagen contraction and collagen remodeling for 4–6 weeks following treatment, resulting in a contour change of the skin (6). Since it was approved by the US Food and Drug Administration in 2002, RF has become an important therapeutic modality for the treatment of periorbital wrinkles in the era of noninvasive skin rejuvenation (7,8). Several studies have evaluated the efficacy of various RF devices for treating periorbital wrinkles (2–4,9). However, noninvasive RF devices have shown to be limited in its efficacy when compared with other invasive surgical procedures or ablative lasers (10). Conventional photographic assessment by investigators is not sensitive enough to evaluate subtle changes in the periorbital skin. Therefore, the need for image analysis devices has emerged to reliably and objectively assess the treatment results (10).

In this study, we retrospectively investigated the efficacy and safety of a microneedle monopolar RF device in the treatment of periorbital wrinkles. The treatment result was evaluated not only by a photographic assessment, but also by an image analysis device that objectively quantified the severity of wrinkles. We further compared the efficacy of these two types of microneedles used in the RF device: a long microneedle (LMN) with a length of 1.5 mm and a short microneedle (SMN) with a length of 0.8 mm.

Methods

This study was a single-center, retrospective cohort study. We reviewed the medical chart of patients who were treated with the microneedle monopolar RF device (AGNES[®], Gwoonsesang Cosmetics.co., Ltd., Seoul, Korea) for periorbital wrinkles between November 2016 and August 2017. Patients were enrolled in this study if they completed three treatment sessions, and if their clinical photographs and VISIA wrinkle score were available at baseline, 1 month, 3 months, and 6 months post-treatment.

Prior to the procedure, the periorbital wrinkle area was gently cleansed with a mild cleanser, wiped with alcohol solution, and dried. After applying an anesthetic cream (EMLA[®]; AstraZeneca, DE, USA) under occlusion for 30 min, the periorbital wrinkle area was marked with a pen. The microneedle RF device consists of a positively charged microneedle and a negatively charged ground pad. The ground pad was attached to the anterior trunk in supine

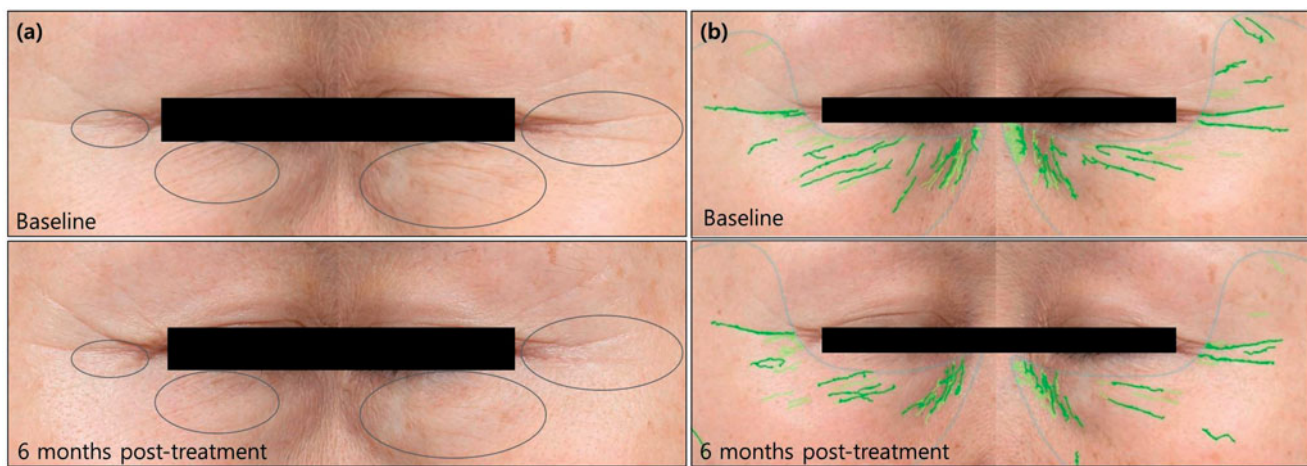


Figure 1. (a) Photographs of a representative patient with periorbital wrinkles treated with microneedle RF. The right side was treated with LMN, while the left side was treated with SMN. A reduction of periorbital wrinkles was observed after three sessions of RF treatment. (b) The severity of wrinkle was quantitatively analyzed using the VISIA system. The VISIA wrinkle score was decreased from 13 to 10 on the right side, from 13 to 9 on the left side. (LMN: long microneedle; RF: radiofrequency; SMN: short microneedle).

position. The two types of microneedles used for treatment were as follows: LMN with a length of 1.5 mm and SMN with a length of 0.8 mm. Each treatment site – right or left – was treated with only one type of microneedle during the treatment sessions. For example, a patient was treated with LMN on both sides, SMN on both sides, or LMN on one side and a SMN on the other side. The choice of microneedle was determined by the operator with a consideration of wrinkle depth. The proximal 0.4 mm of the microneedle was insulated to deliver RF energy without epidermal injury at the point of contact. Microneedles were inserted with 3–5 mm intervals on the marked periorbital wrinkle area. A 1 MHz RF current with an intensity of power level of 5–9 was delivered for a total duration of 120 msec. The treated skin was cooled with an ice cooler after treatment. Each patient underwent three sessions of RF treatment at 4-week intervals.

High-resolution digital photographs were taken before the treatment and at 1-month, 3-month, and 6-month post-treatment follow-ups in the same room with no daylight under controlled ambient conditions. Two dermatologists, who were unaware of the purpose of this study, assessed the photographs using a 6-scale investigator's global assessment (IGA, 1 = none; 2 = mild wrinkles; 3 = mild to moderate wrinkles; 4 = moderate wrinkles; 5 = moderate to severe wrinkles; 6 = severe wrinkles). The clinical photographs were provided to the dermatologists with a non-chronological order. The assessment was made with respect to the area, number, and depth of the periorbital wrinkles. The IGA score was determined by a mean value of IGA from the two dermatologists.

The VISIA wrinkle score was measured at baseline, 1 month, 3 months, and 6 months after the final treatment. The VISIA Complexion Analysis System (Canfield Imaging Systems, Fairfield, NJ, USA) consists of a facial imaging chamber, which is connected to a quantitative analysis software (11). Auto-focusing camera with a resolution of 15 million pixels generates a series of high-resolution photographs in seconds using three kinds of light sources: standard incandescent, ultraviolet, and cross-polarized light (12). The VISIA system identifies the total size, area, and intensity of wrinkles under a standard flash light. The severity of wrinkles is provided as a wrinkle score, ranging from 0 to 100. We routinely performed VISIA measurement in the clinic to provide quantitative assessment of patients' wrinkle condition. Any adverse events

from RF treatment were collected by reviewing the medical records.

Ethics statement

This study was conducted in accordance with the Declaration of Helsinki and International Conference on Harmonization and Good Clinical Practice Guidelines. It was reviewed and approved by the local institutional review board (P01-201902-21-008).

Statistical analysis

SPSS Statistics 21.0 (IBM SPSS Inc., Chicago, IL, USA) was used for all data analyses. *p* values were obtained by paired *t* test to determine the difference in the IGA and VISIA wrinkle score at each visit compared with the baseline. Student's *t* test was used to evaluate the difference in the IGA and VISIA wrinkle score between the LMN and SMN group at each visit. *p* values were considered as statistically significant at the alpha level of 0.05.

Results

A total of 21 patients with 42 treatment sites were included in this study. There were 18 female and 3 male patients with Fitzpatrick skin type III–IV. The mean age was 50.24 ± 10.99 with a range of 31–to 67 years. As shown in Figure 1, a reduction of periorbital wrinkles was observed after three sessions of RF treatment compared with the baseline. The IGA score was improved at 1 month (3.06 ± 0.85), 3 months (2.76 ± 0.81), and 6 months (2.65 ± 0.82) after treatment compared with the baseline (3.57 ± 0.93) (Figure 2(a)). A consistent and progressive improvement in the IGA score was demonstrated from the baseline to 6 months post-treatment. Improvement in the VISIA score was also observed at 3 months (9.21 ± 5.06) and 6 months (9.24 ± 4.47) compared with the baseline (10.86 ± 5.63) (Figure 2(b)). Except for a slight elevation at 6 month post-treatment, the VISIA score also showed a progressive improvement during the study period.

Twenty-one sites were treated with LMN (the LMN group), and the other 21 sites were treated with SMN (the SMN group). The IGA scores at the baseline were not significantly different between the two groups. Compared with the baseline (3.64 ± 0.94 and

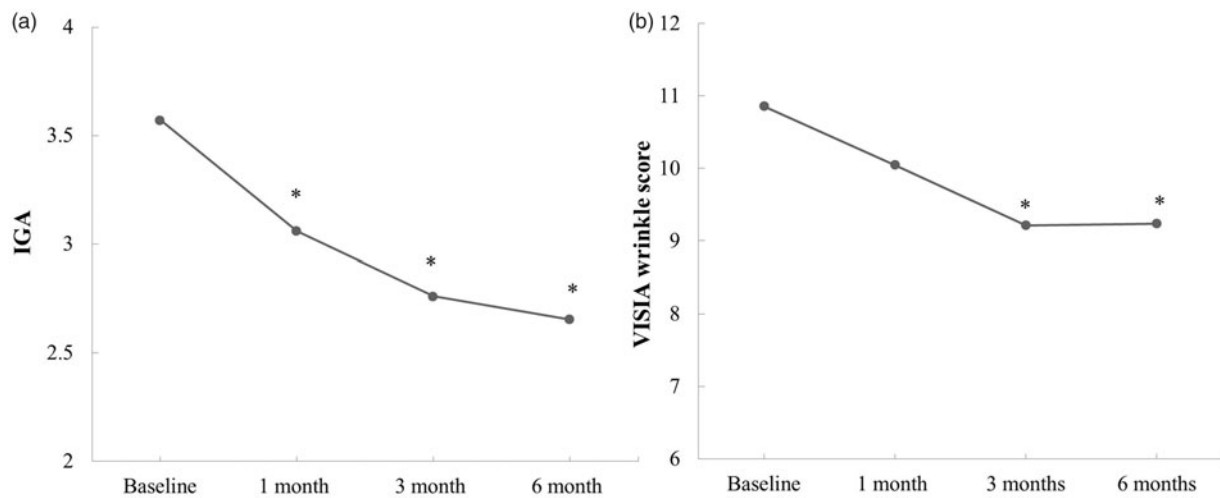


Figure 2. (a) IGA score was significantly improved at 1 month, 3 months, and 6 months after treatment. Consistent and progressive improvement in the IGA score was demonstrated from the baseline to 6 months after treatment. (b) Significant improvement in the VISIA score was also observed at 3 months and 6 months post-treatment. *Statistically different compared with the baseline ($p < .05$) (IGA: investigator's global assessment).

3.50 ± 0.95), both of the LMN and SMN groups showed improvements in the IGA score at 1 month (3.19 ± 0.83 and 2.92 ± 0.87), 3 months (2.83 ± 0.86 and 2.96 ± 0.77), and 6 months (2.67 ± 0.78 and 2.64 ± 0.87 , respectively) post-treatment (Figure 3(a)). A statistically significant difference in the IGA score was not observed between the two groups at each follow-up. There was no significant difference in the baseline VISIA wrinkle score between the LMN and SMN group. Six months post-treatment, the VISIA wrinkle score was improved in the LMN group (from 10.24 ± 4.52 to 7.86 ± 3.80) (Figure 3(b)). In contrast, no significant change in the VISIA wrinkle score was observed in the SMN group throughout the study period. The VISIA wrinkle score at 6 months post-treatment was significantly lower in the LMN group (7.86 ± 3.80) than in the SMN group (10.62 ± 4.74).

With respect to safety, all patients tolerated the procedure well, reporting none to minimal pain. Mild irritation (38.1%), bruise (28.6%), swelling (14.3%), paresthesia (14.3%), and eyelid tremor (14.3%) were observed; however, they were transient and resolved spontaneously at 1-month follow-up after the treatment. Post-inflammatory hyperpigmentation (PIH), scarring, or any other serious adverse events was not reported throughout the study period.

Discussion

Chronic ultraviolet (UV) exposure, repetitive orbicularis oculi muscle contraction, and intrinsic aging process in combination are attributable to the formation of periorbital wrinkles (1,2,4). Photoaging caused by cumulative UV exposure and intrinsic aging process result in thinned skin and reduced amount of collagen fibers (13). Orbicularis oculi muscles, which run around each eye, cause crumpling of the overlying skin as they contract (1). Although periorbital wrinkles are reversible in young age, reversibility becomes more difficult as wrinkles become more static from the aging process.

However, treatment of periorbital wrinkles is challenging because of its anatomical significance and delicate nature (1). Efficient and safe therapeutic modalities, such as botulinum toxin injections and energy-based devices, have been introduced to manage periorbital wrinkles while avoiding risks of eye injury, ectropion, or permanent scarring (2–4). While botulinum toxin injection inhibits the contraction of the orbicularis oculi muscles,

energy-based devices, such as ablative and non-ablative lasers, stimulate neocollagenesis, thereby reversing the aging process. Ablative lasers (carbon dioxide and erbium:yttrium aluminum garnet lasers) induce injury not only to the dermis but also to the epidermis, causing higher frequency of complications and longer downtime (14). Although non-ablative fractional lasers (1450 nm, 1550 nm, 1927 nm) reduce downtime and occurrence of adverse events compared with ablative lasers, PIH still remains problematic, especially in treating Asian skin (2,15). PIH was reported in up to 32% of Asian patients treated with non-ablative fractional laser resurfacing (16).

Unlike the non-ablative lasers, RF devices do not rely on the chromophore for efficacy or safety, and thus, are suitable for all skin types (17). RF devices utilize electrical current to produce heat (5). Tissue resistance converts the electrical current of RF to thermal energy. Thermal damage induces collagen shrinkage immediately post-RF treatment (5). Fragmented collagen is degraded by matrix metalloproteinases, and replaced by newly produced collagen, which occurs for several months (5,18). Increased levels of type I and III collagen in the dermis were reported in patients undergoing treatment using the monopolar RF device (19). As an alternative to non-ablative lasers, RF devices have been vigorously used in many aesthetic fields, such as skin lifting and tightening, body contouring, and lipolysis (20).

Several electrode configurations are available now in the RF system; monopolar, bipolar and multipolar RF. In the monopolar RF devices, electrical current passes from a monopolar electrode, which is in contact with the skin, to a grounding pad. In contrast, bipolar and multipolar RF devices produce electrical current between two or more electrodes which are in contact with the skin. They enable controlled distribution of the RF current, which is limited to the tissue between the electrodes. However, limited depth of penetration, which is approximately half of the distance between the electrodes, results in reduced efficacy of bipolar and multipolar RF devices compared with monopolar RF devices (21,22).

In this study, we evaluated the efficacy and safety of monopolar RF device in the treatment of periorbital wrinkles. A statistical analysis revealed a significant difference in the IGA and VISIA wrinkle score between the baseline and 3- and 6-month follow-up after the final treatment. The RF device uses two types of micro-needles as its positive electrode to control the depth where RF

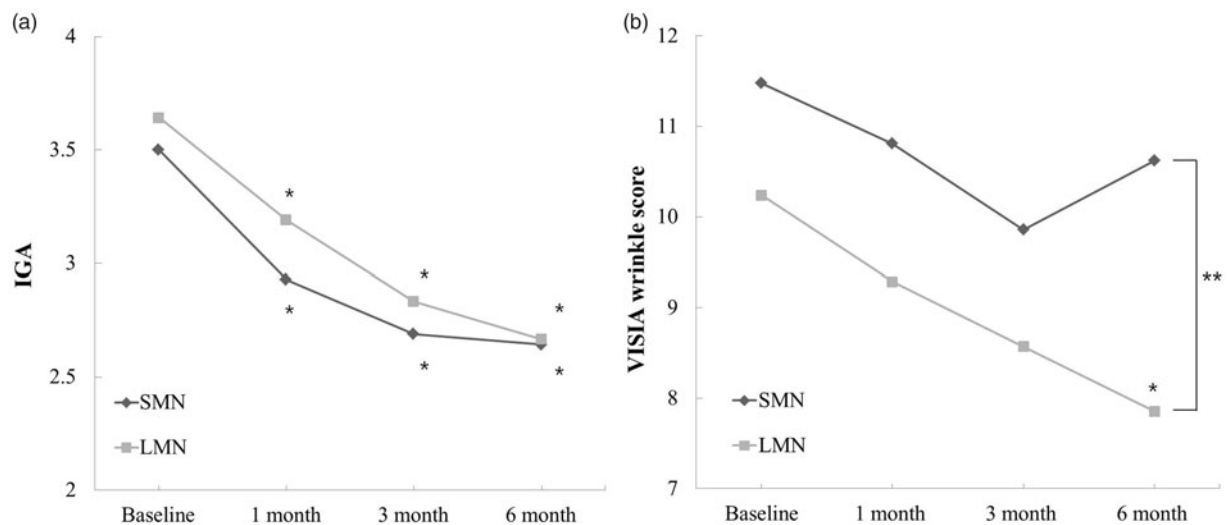


Figure 3. (a) Both the LMN and SMN groups showed significant improvements in the IGA score at 1 month, 3 months, and 6 months after treatment. (b) At 6 months after treatment, the VISIA wrinkle score was significantly improved in the LMN group. In contrast, no significant change in the VISIA wrinkle score was observed in the SMN group throughout the study period. The VISIA wrinkle score at 6 months after treatment was significantly lower in the LMN group than in the SMN group. *Statistically different compared with the baseline ($p < .05$). **Statistically different between the LMN and SMN groups ($p < .05$) (IGA: investigator's global assessment; LMN: long microneedle; SMN: short microneedle).

current is produced. To protect the epidermis from thermal injury, the proximal 0.4 mm area of the microneedles is insulated. The shorter length of insulation compared with other microneedle fractional RF devices enables the transfer of RF energy to more superficial tissues, and thus is suitable for the treatment of eyelid skin, whose depth is only around 1 mm (23). The T-shaped shoulder of the microneedle functions as a stopper, which enables to transfer RF energy into the same depth, regardless of the different sessions or operators (23).

Although monopolar RF has been criticized for causing pain during the procedure, with the help of topical anesthetic cream, it has been considered tolerable, with none to minimal pain reported (22). There were mild and transient adverse events that resolved spontaneously at 1-month follow-up post-treatment. No serious adverse events occurred during the study. The insulated proximal part of the microneedle might contribute to the prevention of serious adverse events, especially PIH and scarring, which are related to epidermal damage.

The VISIA system is one of the most widely used imaging analysis devices in the dermatology clinics and esthetic industry (24,25). It generates a series of high-resolution images in seconds, using incandescent light, ultraviolet light, and polarized light (12). In our clinic, we routinely use the VISIA system to assess patient's face to provide information on their overall skin condition, including spots, wrinkles, texture, pore size, ultraviolet spots, porphyrin, brown spots, and red areas. In comparison with the age- and skin type-matched controls, the percentile where each patient falls on the distribution is provided as a score ranging from 0 to 100 to quantitatively illustrate the severity of each skin characteristic (11). Therefore, the VISIA system detects any changes of skin conditions more objectively than the photographic assessment method, which has a limited number of scales (6).

In this study, VISIA measurement revealed a statistical difference in the treatment outcome between the LMN and SMN group. Although photographic assessment by the investigators did not discriminate any difference in the efficacy of the LMN and SMN, VISIA measurement showed a significantly lower VISIA wrinkle score in the LMN group than in the SMN group at 6 months post-treatment. Stimulation of collagen production at the deep

dermis by LMN may have contributed to the results. Since the electrical current is focused near the tip of the electrodes in the monopolar configuration, LMN might produce a higher level of thermal injury to the deep dermis than SMN (26). In addition, skin needling itself could stimulate collagen production through wound healing (27). Skin needling with LMN, which could penetrate the skin up to 1.5 mm, might result in full-thickness dermal injury and induce neocollagenesis in the deeper dermis than SMN.

The primary limitation of our study is its retrospective study design. However, we assessed the treatment results not only with photographic assessment by blinded investigators, but also with VISIA measurement. Moreover, we demonstrated a difference in the treatment results between the two types of microneedles for the RF device. Although there have been several studies demonstrating the efficacy of microneedle RF devices for treating periorbital wrinkles, our study, to the best of our knowledge, is the first to compare the efficacy between the two types of microneedles with different lengths (2,4).

Conclusion

In this study, we evaluated the efficacy and safety of a microneedle monopolar RF device in the treatment of periorbital wrinkles. Both photographic assessment and VISIA measurement revealed a reduction in periorbital wrinkles after three sessions of RF treatment. Although there were mild and transient adverse events, no serious complications, such as scarring or PIH, occurred. LMN was more effective in reducing the VISIA wrinkle score than its short counterpart.

Disclosure statement

Gun Young Ahn and Woo Sun Jang are employed in Gwoonsesang Cosmetics.co., Ltd. Soon-Hyo Kwon, Ji-Young Choi, Jung-Won Shin, Jung-Im Na, Kyoung-Chan Park and Chang-Hun Huh declare no conflict of interest.

References

- Manaloto RM, Alster TS. Periorbital rejuvenation: a review of dermatologic treatments. *Dermatol Surg.* 1999;25(1):1–9.
- Kim JK, Roh MR, Park GH, et al. Fractionated microneedle radiofrequency for the treatment of periorbital wrinkles. *J Dermatol.* 2013;40(3):172–176.
- Han SH, Yoon YM, Lee YW, et al. Usefulness of monopolar thermal radiofrequency treatment for periorbital wrinkles. *Ann Dermatol.* 2018;30(3):296–303.
- Lee SJ, Kim JI, Yang YJ, et al. Treatment of periorbital wrinkles with a novel fractional radiofrequency microneedle system in dark-skinned patients. *Dermatol Surg.* 2015;41(5):615–622.
- Elsaie ML, Choudhary S, Leiva A, et al. Nonablative radiofrequency for skin rejuvenation. *Dermatol Surg.* 2010;36(5):577–589.
- Al-Muriesh M, Zhang X, Wang Q, et al. Efficacy of noninvasive multisource radiofrequency treatment on periorbital rhytids using an imaging device. *Lasers Surg Med.* 2019;51(3):251–255.
- Fitzpatrick R, Geronemus R, Goldberg D, et al. Multicenter study of noninvasive radiofrequency for periorbital tissue tightening. *Lasers Surg Med.* 2003;33(4):232–242.
- Abraham MT, Chiang SK, Keller GS, et al. Clinical evaluation of non-ablative radiofrequency facial rejuvenation. *J Cosmet Laser Ther.* 2004;6(3):136–144.
- Roh NK, Yoon YM, Lee YW, et al. Treatment of periorbital wrinkles using multipolar fractional radiofrequency in Korean patients. *Lasers Med Sci.* 2017;32(1):61–66.
- Javate RM, Grantoza CL, Buyucan KF. Use of an imaging device after nonablative radiofrequency (Pelleve): treatment of periorbital rhytids. *Ophthalmic Plast Reconstr Surg.* 2014;30(6):499–503.
- Goldsberry A, Hanke CW, Hanke KE. VISIA system: a possible tool in the cosmetic practice. *J Drugs Dermatol.* 2014;13(11):1312–1314.
- Linming F, Wei H, Anqi L, et al. Comparison of two skin imaging analysis instruments: The VISIA((R)) from Canfield vs the ANTERA 3D((R)) CS from Miravex. *Skin Res Technol.* 2018;24(1):3–8.
- Warren R, Gartstein V, Kligman AM, et al. Age, sunlight, and facial skin: a histologic and quantitative study. *J Am Acad Dermatol.* 1991;25(5 part 1):751–760.
- Lolis MS, Goldberg DJ. Assessment of safety and efficacy of a bipolar fractionated radiofrequency device in the treatment of periorbital rhytides. *J Cosmet Laser Ther.* 2014;16(4):161–164.
- Lipozencic J, Mokos ZB. Will nonablative rejuvenation replace ablative lasers? Facts and controversies. *Clin Dermatol.* 2013;31(6):718–724.
- Chan HH, Manstein D, Yu CS, et al. The prevalence and risk factors of post-inflammatory hyperpigmentation after fractional resurfacing in Asians. *Lasers Surg Med.* 2007;39(5):381–385.
- el-Domyati M, el-Ammawi TS, Medhat W, et al. Radiofrequency facial rejuvenation: evidence-based effect. *J Am Acad Dermatol.* 2011;64(3):524–535.
- Orringer JS, Kang S, Johnson TM, et al. Connective tissue remodeling induced by carbon dioxide laser resurfacing of photodamaged human skin. *Arch Dermatol.* 2004;140(11):1326–1332.
- Yokoyama Y, Akita H, Hasegawa S, et al. Histologic study of collagen and stem cells after radiofrequency treatment for aging skin. *Dermatol Surg.* 2014;40(4):390–397.
- Beasley KL, Weiss RA. Radiofrequency in cosmetic dermatology. *Dermatol Clin.* 2014;32(1):79–90.
- Sadick NS, Nassar AH, Dorizas AS, et al. Bipolar and multipolar radiofrequency. *Dermatol Surg.* 2014;40(Suppl 12):S174–S179.
- Lolis MS, Goldberg DJ. Radiofrequency in cosmetic dermatology: a review. *Dermatol Surg.* 2012;38(11):1765–1776.
- No YA, Kim BJ, Kim MN, et al. The clinical experience and efficacy of radiofrequency device for wrinkle treatment. *Lasers Med Sci.* 2017;32(6):1449–1450.
- Ichibori R, Fujiwara T, Tanigawa T, et al. Objective assessment of facial skin aging and the associated environmental factors in Japanese monozygotic twins. *J Cosmet Dermatol.* 2014;13(2):158–163.
- Akita H, Sasaki R, Yokoyama Y, et al. The clinical experience and efficacy of bipolar radiofrequency with fractional photothermolysis for aged Asian skin. *Exp Dermatol.* 2014;23(Suppl 1):37–42.
- Sadick NS, Makino Y. Selective electro-thermolysis in aesthetic medicine: a review. *Lasers Surg Med.* 2004;34(2):91–97.
- Fabbrocini G, Fardella N, Monfrecola A, et al. Acne scarring treatment using skin needling. *Clin Exp Dermatol.* 2009;34(8):874–879.