

## Use of Fractionated Microneedle Radiofrequency for the Treatment of Inflammatory Acne Vulgaris in 18 Korean Patients

SANG JU LEE, MD, PhD,<sup>\*</sup> JA WOONG GOO, MD,<sup>†</sup> JAEYONG SHIN, MD,<sup>‡</sup> WON SOON CHUNG, MD,<sup>\*</sup> JIN MOON KANG, MD,<sup>\*</sup> YOUNG KOO KIM, MD,<sup>\*</sup> AND SUNG BIN CHO, MD, PhD<sup>‡</sup>

---

**BACKGROUND** Nonablative radiofrequency (RF) devices have been shown to be clinically effective for the treatment of moderate to severe acne lesions.

**OBJECTIVE** To evaluate the efficacy and safety of a fractionated microneedle RF device in the treatment of inflammatory acne vulgaris.

**METHODS** Eighteen patients (15 male, 3 female; mean age 27, range: 19–33; Fitzpatrick skin type IV) with moderate to severe acne vulgaris who were treated with two sessions of fractionated microneedle RF at 1-month intervals were enrolled in this study.

**RESULTS** Evaluation of improvement, which took into account number of inflammatory acne lesions, showed that two of the 18 patients had grade 4 clinical improvement, eight had grade 3 improvement, and six had grade 2 improvement. Improvement scores in terms of lesion severity were also evaluated. One of the 18 patients had grade 4 clinical improvement, eight grade 3, and seven grade 2. No patient had worsening of inflammatory acne lesions.

**CONCLUSION** Fractionated microneedle RF can have a positive therapeutic effect on inflammatory acne vulgaris and related scars. In addition, this technique does not worsen active acne lesions.

*The authors have indicated no significant interest with commercial supporters.*

---

Four major factors contribute to acne formation: excessive sebum production, follicular epithelial hyperproliferation and keratin plugs, *Propionibacterium acnes*, and follicular and perifollicular inflammation. These are the main targets of currently available treatment modalities for acne vulgaris.<sup>1,2</sup> Pharmacologic therapies such as topical antibiotics, oral antibiotics, topical retinoids, and oral retinoids are the mainstays of treatment, but they commonly require long-term use and can be associated with significant side effects, including the emergence of resistant strains of *P. acnes*.<sup>2–6</sup> Nonpharmacologic treatments have been increasingly used for acne vulgaris independently or in combination with medical therapeutic modalities.

Although laser or light therapy is usually used for acne scars rather than active lesions, the efficacy and safety of various laser and light devices, including pulsed dye laser, nonablative 1,450-nm diode laser, and intense pulsed light, for the treatment of inflammatory acne vulgaris have been reported. Pulsed dye lasers appear to kill *P. acnes*, and hemoglobin absorbs laser energy, which reduces vascularity and modulates the inflammatory process associated with acne.<sup>1,3,4,6</sup> The effects of nonablative 1,450-nm diode lasers on acne vulgaris have been characterized by thermal damage to the sebaceous glands and a resultant reduction in sebum production.<sup>2,5,6</sup>

<sup>\*</sup>Yonsei Star Skin and Laser Clinic, Seoul, Korea; <sup>†</sup>Department of Dermatology, Yonsei University Wonju College of Medicine, Wonju, Korea; <sup>‡</sup>Department of Dermatology and Cutaneous Biology Research Institute, Yonsei University College of Medicine, Seoul, Korea

Nonablative radiofrequency (RF) devices have also been used effectively for the treatment of moderate to severe inflammatory acne vulgaris.<sup>7</sup> It has been suggested that the mechanism of action of nonablative RF is mainly a reduction of sebaceous gland activity and the promotion of dermal architecture remodeling by thermal stimulation, namely thermotherapy.<sup>7</sup> Our study group reported previously that most patients with suppurative skin lesions, including inflammatory acne vulgaris, experienced clinical improvement in the number and severity of lesions after ablative 10,600-nm carbon dioxide fractional laser treatment.<sup>8</sup> In this report, we demonstrate the efficacy of a fractionated microneedle RF device in 18 Korean patients with active acne lesions through a retrospective analysis of clinical photographs and post-therapy recovery time.

**Methods**


Eighteen patients (15 male, 3 female; mean age 23.9, range: 21–34; Fitzpatrick skin type: IV) with moderate to severe acne vulgaris treated using frac-

tionated microneedle RF were retrospectively reviewed in this study. Patient characteristics are summarized in Table 1. Patients were excluded from the study if they had recently received systemic retinoids, 1,450-nm diode laser treatment, 595-nm pulsed dye laser treatment, intense pulsed light photodynamic therapy, nonablative erbium-glass fractional laser treatment, or ablative 10,600-nm carbon dioxide fractional laser treatment within 6 months. Patients were also excluded if they had been treated with systemic and topical antibiotics, intralesional corticosteroid injections, incision and drainage, or surgical excision within 1 month. Patients with a high probability of becoming pregnant or a propensity for keloids or immunosuppression were excluded.

Patients were treated with two sessions of fractionated microneedle RF (Scarlet, Viol, Seoul, Korea; Figure 1) at 1-month intervals. Before application of local anesthesia, the face was cleansed with a mild soap and 70% alcohol. A topical eutectic mixture of 2.5% lidocaine hydrochloric acid and

**TABLE 1. Patient Characteristics at Baseline and Clinical Outcomes Following Fractionated Microneedle Radiofrequency Treatment**

Patient Number	Sex	Age	Clinical Diagnosis	Global Improvement Score		
				No. Lesions	Severity	Overall Skin Pattern
1	M	23	Acne vulgaris, pustular, severe	1	1	2
2	M	22	Acne vulgaris, pustular, severe	3	2	2
3	F	22	Acne vulgaris, pustular, moderate	3	2	3
4	M	29	Acne vulgaris, pustular, severe	2	3	2
5	M	22	Acne vulgaris, pustular, moderate	2	3	3
6	M	21	Acne vulgaris, pustular, moderate	4	3	4
7	M	23	Acne vulgaris, pustular, moderate	4	3	4
8	M	25	Acne vulgaris, pustular, moderate	2	2	2
9	M	23	Acne vulgaris, pustular, moderate	3	2	3
10	M	23	Acne vulgaris, pustular, moderate	2	2	2
11	M	22	Acne vulgaris, pustular, moderate	3	2	3
12	M	21	Acne vulgaris, pustular, moderate	2	3	3
13	M	24	Acne vulgaris, pustular, moderate	3	1	3
14	M	23	Acne vulgaris, pustular, severe	3	3	2
15	M	22	Acne vulgaris, pustular, moderate	3	2	3
16	M	26	Acne vulgaris, pustular, moderate	3	4	3
17	F	34	Acne vulgaris, pustular, moderate	2	3	1
18	F	26	Acne vulgaris, pustular, moderate	1	3	2



**Figure 1.** (A) The handpiece of the fractionated microneedle radiofrequency device equipped with microneedle tip and (B) a close up view of a disposable microneedle tip.

2.5% prilocaine (AstraZeneca AB, Södertälje, Sweden) was applied to the entire face under occlusion 1 hour before laser therapy. The treatment settings were 3-mm microneedle penetrating depth; intensity, 7; and RF conduct time (off/on/off), 100/500/100 ms. RF was applied over the entire face for two passes, and an additional pass was delivered to severe pustular lesions. Patients with a history of herpes virus infection were prophylactically prescribed oral valacyclovir hydrochloride (Valtrex, GlaxoSmithKline, Research Triangle Park, NC) for 3 days. The use of a non-comedogenic moisturizer several times daily for a few days after each treatment session was recommended to promote wound healing and prevent dryness. Patients were instructed to avoid overexposure to sunlight and to use a broad-spectrum sunscreen after the post-therapy crusting subsided. They were also instructed to avoid the use of any systemic or topical retinoids and antibiotics during the course of treatment.

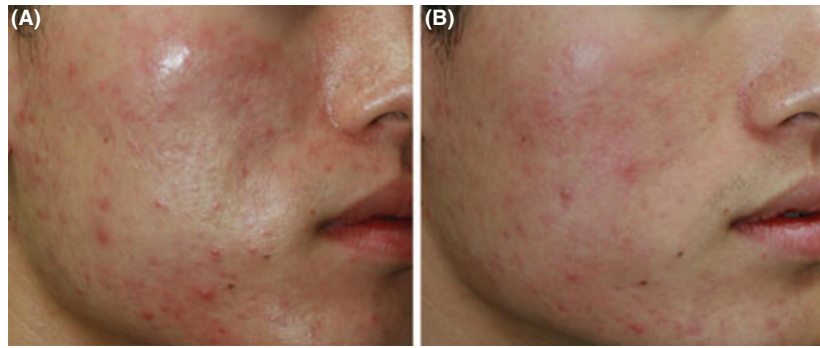
Photographs were taken using identical camera settings, lighting, and patient positioning at baseline and 2 months after the last treatment. Two dermatologists performed objective clinical assessments in a blinded fashion by comparing before-and-after photos in nonchronological order using a global improvement scale (grade 0, worsened; grade 1, 0–25% = minimal improvement or steady state; grade 2, 26–50% = moderate improvement; grade 3, 51–75% = marked improvement; and grade 4,

>75% = near total improvement). Improvement scores, which considered the number, severity, and overall skin pattern of the inflammatory acne lesions, were separately recorded as described in our previous study.<sup>8</sup> The overall skin pattern was evaluated according to scar improvement, enlarged facial pores, skin tone, and texture. Investigators assessed and recorded possible side effects, including bleeding, oozing, post-therapy dyschromia, scaling, crusting, and erythema at each visit (at 1- to 2-week intervals). Two months after the final treatment, the reported side effects were reassessed and analyzed.

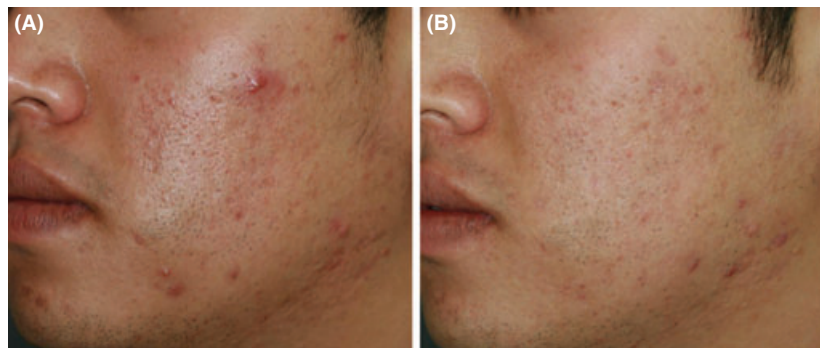
## Results

Improvement scores that considered the number of inflammatory acne lesions evaluated 2 months after the final treatment revealed that two of the 18 patients had grade 4 clinical improvement (Table 1, Figures 2 and 3), eight grade 3, six grade 2 (Figure 4), and two grade 1. Worsening of the inflammatory acne lesions was not observed in any patient. The mean clinical improvement score for the number of active acne lesions based on dermatologic clinical assessment was 2.6.

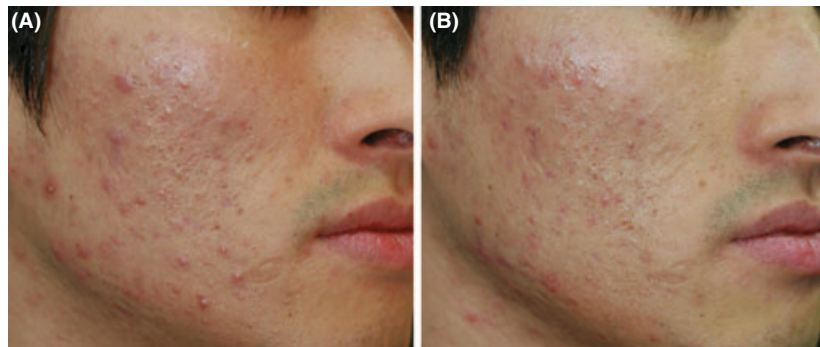
Improvement scores that considered the severity of the lesions were also evaluated. One of the 12 patients had grade 4 clinical improvement, eight grade 3, seven grade 2, and two grade 1. No patient had worsening of lesions. The mean clinical



**Figure 2.** Case 6: Moderate pustular acne vulgaris in a 21-year-old man before (A) and 2 months after (B) fractionated microneedle radiofrequency treatment. This patient had an overall clinical improvement score of 4.



**Figure 3.** Case 7: Moderate pustular acne vulgaris in a 23-year-old woman before (A) and 2 months after (B) fractionated microneedle radiofrequency treatment. This patient had an overall clinical improvement score of 4.



**Figure 4.** Case 4: Severe pustular acne vulgaris in a 29-year-old man before (A) and 2 months after (B) fractionated microneedle radiofrequency treatment. This patient had an overall clinical improvement score of 2.

improvement score for the severity of the lesions was 2.4.

Overall skin pattern was improved, with two of 12 patients having grade 4 clinical improvement, eight grade 3, seven grade 2, and one patient grade 1.

The mean clinical improvement score in overall skin pattern was 2.6.

Side effects included pain during laser treatment, post-treatment crusting and scaling, edema, post-therapy erythema, and oozing from the treated

sites. Post-therapy bleeding, crusting (Figure 5), and scaling improved spontaneously in 5 days. Major side effects were not noted.

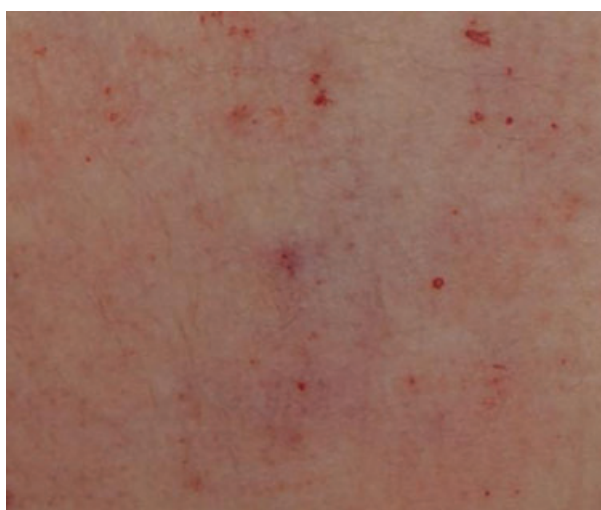## Discussion

RF-based devices have been used for the treatment of various dermatologic conditions, including wrinkles, atrophic scars, hypertrophic scars and keloids, rosacea, vascular lesions, and inflammatory acne lesions.<sup>7,9</sup> The mechanism of action of these devices is thought to be related to the fact that water, collagen, melanin, and dermal microvasculature absorb RF energy, producing a bulk heating effect on the dermis and inducing cellular mediator and growth factor secretion, which results in wound healing.<sup>9</sup>

Ruiz-Esparza and Gomez demonstrated that non-ablative RF can also be used as a safe and effective treatment for moderate to severe acne vulgaris.<sup>7</sup> According to their report, an excellent response was noted in more than 80% of participants who underwent nonablative RF treatments, and no remarkable side effects were detected.<sup>7</sup> The authors suggested that thermal stimulation produced by the RF-based system seemed to inhibit sebaceous gland

activity and stimulate dermal architecture remodeling, resulting in clinical improvement in the inflammatory acne lesions.<sup>7</sup>

Hantash and colleagues<sup>10</sup> first demonstrated the effects of the minimally invasive RF device, a bipolar microneedle electrode system, on human skin. The authors created radiofrequency thermal zones in the dermis using microneedle electrode pairs.<sup>10</sup> In the present study, a fractionated microneedle RF was used for inflammatory acne vulgaris and its related dermatologic conditions, including acne scars and enlarged facial pores. The therapeutic effects of this device may have been the result of volumetric tissue heating by the RF, as well as from collagen induction by the stamping microneedles. The microneedle of the RF device used in the present study was not insulated, whereas that of RF device used in the previous report<sup>10</sup> was insulated proximally to protect the epidermis from RF heating at the insertion sites. Possible side effects associated with RF heating on the epidermis, including burning, noticeable crusting, prolonged erythema, postinflammatory hyperpigmentation, and scarring, were not observed with the use of a RF device with noninsulated microneedles. Instead, therapeutic effects on the epidermis were observed, especially textural improvement.



**Figure 5.** Post-therapy bleeding and crusting immediately after fractionated microneedle radiofrequency treatment.

Fractionated RF seems to provide higher volumetric heating and deeper heat diffusion than ablative and nonablative laser-based fractional devices. Skin needling or needle dermabrasion using microneedles has been reported to stimulate migration and proliferation of keratinocytes and fibroblasts by inducing the release of several growth factors.<sup>11</sup> In addition, making closer holes induces regeneration and realignment of irregular and thick collagen bundles through physical breakage, resulting in better clinical scar and skin texture.<sup>12</sup>

The Korea Food and Drug Administration (KFDA) has approved the fractionated microneedle RF device (Scarlet, Viol) used in this study for use in dermatologic procedures, and more than 150

devices (Scarlet, Viol) have been used commercially for skin rejuvenation and for the treatment of wrinkles and atrophic scars in Asian countries, including Korea. In addition, more than five kinds of fractionated microneedle RF device have been introduced and are widely used in Korea. New microneedle RF-based devices are still being developed, and the market is growing rapidly.

The present study demonstrated the efficacy and safety of a fractionated microneedle RF device in the treatment of inflammatory acne lesions. We think that the advantages of therapy using this device over other therapies are the combined effects of volumetric tissue heating by the RF and collagen induction by the stamping microneedles. The inhibition of sebaceous gland activity and the stimulation of follicular epithelial and dermal architecture remodeling are mechanisms that might result in the clinical improvement of inflammatory acne lesions when using fractional RF-induced dermal heating and skin needling.

We believe that a fractionated microneedle RF device can deliver therapeutic energy to dermal tissues through microneedles more safely and effectively than nonablative RF devices or ablative 10,600-nm carbon dioxide fractional lasers. In our experience, the side effects of a fractionated microneedle RF, especially post-therapy crusting and scaling, were much less noticeable than with ablative 10,600-nm carbon dioxide fractional laser treatment. Most patients treated the treatment-associated pain using topical anesthetic creams. Post-therapy pinpoint bleeding was much more transient than with skin needling or needle dermabrasion. In addition, because of a low risk of a long recovery time, edema, prolonged erythema, post-therapy dyschromias, and scarring, a fractionated microneedle RF device is safe to be used in Asian patients, although prospective studies should

be conducted in the future to confirm our findings.

## References

1. Harper JC. An update on the pathogenesis and management of acne vulgaris. *J Am Acad Dermatol* 2004;51:S36–8.
2. Glaich AS, Friedman PM, Jih MH, Goldberg LH. Treatment of inflammatory facial acne vulgaris with combination 595-nm pulsed-dye laser with dynamic-cooling-device and 1,450-nm diode laser. *Lasers Surg Med* 2006;38:177–80.
3. Seaton ED, Charakida A, Mouser PE, Grace I, et al. Pulsed-dye laser treatment for inflammatory acne vulgaris: randomized controlled trial. *Lancet* 2003;362:1347–52.
4. Munavalli GS, Weiss RA. Evidence for laser- and light-based treatment of acne vulgaris. *Semin Cutan Med Surg* 2008;27:207–11.
5. Orringer JS, Kang S, Hamilton T, Schumacher W, et al. Treatment of acne vulgaris with a pulsed dye laser a randomized controlled trial. *JAMA* 2005;291:2834–9.
6. Rinaldi F. Laser: a review. *Clin Dermatol* 2008;26:590–601.
7. Ruiz-Esparza J, Gomez JB. Nonablative radiofrequency for active acne vulgaris: the use of deep dermal heat in the treatment of moderate to severe active acne vulgaris (thermotherapy): a report of 22 patients. *Dermatol Surg* 2003;29:333–9.
8. Cho SB, Jung JY, Ryu DJ, Lee SJ, et al. Effects of ablative 10,600-nm carbon dioxide fractional laser therapy on suppurative diseases of the skin: a case series of 12 patients. *Lasers Surg Med* 2009;41:550–4.
9. Elsaie ML, Choudhary S, Leiva A, Nouri K. Nonablative radiofrequency for skin rejuvenation. *Dermatol Surg* 2010;36:577–89.
10. Hantash BM, Renton B, Berkowitz RL, Stridde BC, et al. Pilot clinical study of a novel minimally invasive bipolar microneedle radiofrequency device. *Lasers Surg Med* 2009;41:87–95.
11. Fabbrocini G, Fardella N, Monfrecola A, Proietti I, et al. Acne scarring treatment using skin needling. *Clin Exp Dermatol* 2009;34:874–9.
12. Cho SB, Lee SJ, Kang JM, Kim YK, et al. The treatment of burn scar-induced contracture with the pinhole method and collagen induction therapy: a case report. *J Eur Acad Dermatol Venereol* 2008;22:513–4.

---

Address correspondence and reprint requests to: Sung Bin Cho, MD, PhD, Department of Dermatology and Cutaneous Biology Research Institute, Yonsei University College of Medicine, 250 Seongsanno, Seodaemun-gu, Seoul 120–752, Korea, or e-mail: sbcho@yuhs.ac